
**


*

*

**

// :

// :



Tamil Nadu

()

.()

:

gag

:

()

(Claw hand)

()

()

MRI

Amyotrophic

)

Lateral Sclerosis (ALS)

(

()

ALS :

| MMND | ALS | |
|------|-----|--|
| | | |
| | | |
| | | |
| | | |
| | | |
| | | |
| | | |

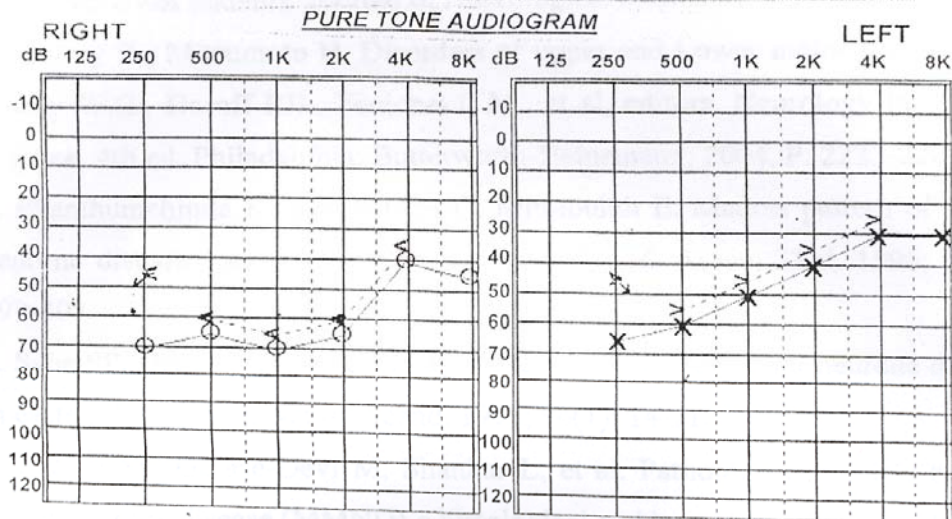
Banglore

()

()

کلینیک تخصصی شنوایی شناسی

NAME: LASTNAME: AGE: ۶۱ سال DATE: ۸۲/۲/۱۴



شکل ۱: ادیومتری بیماری که موید کاهش شنوایی حسی - عصبی است

EMG Summary Table

| | IA | Fib | Spontaneous | | Amp | Dur. | MUAP Recruitment | |
|---------------------|----|------|-------------|------|-----|-----------|------------------|---------|
| | | | PSW | Fasc | | | PPP | Pattern |
| L. GENERAL MUSCLE | N | None | None | None | N | N | N | N |
| R. TIB ANTERIOR | N | 2+ | 1+ | None | N | Increased | 2+ | Reduced |
| R. RECT FEMORIS | N | None | None | None | N | N | N | N |
| R. EXT HALL LONG | N | 1+ | 1+ | None | N | N | 2+ | Reduced |
| R. EXT DIG BREVIS | N | None | None | None | N | N | N | N |
| L. TIB ANTERIOR | N | None | None | None | N | N | N | N |
| R. FIRST D INTEROSS | N | None | None | None | N | N | N | N |
| R. ABD POLL BREVIS | N | 2+ | None | None | N | N | 1+ | Reduced |

شکل ۲: نتیجه الکترومیوگرافی بیمار که موید دنرواسیون می باشد

. ()

()

. ()

1. Gourie- Devi M, Nalini A. Madras Motor Neurone Disease Variant, Clinical Feature of Seven Patients. *Journal of Neurological Sciences* 2003; 209: 13-17.

2. Murray B, Mitsumoto H. Disorders of Upper and Lower Motor Neurons. In: Bradley W G, Daroff RB, Fenichel CM, et al (editors). *Neurology in Clinical Practice*. 4th ed. Philadelphia; Butterworth-Heinemann, 2004: 2233-2267.

3. Phanthumchinda K, Supcharoen O, Mitrabukdi E. Madras Pattern of Motor Neurone Disease: Case Report from Thailand. *J med Assoc Thai* 1996; 79(6):399-402.

4. Saha SP, Das SK, Gargo Padhyay PK, et al. Pattern of Motor Neurone Disease in Eastern India. *Acta Neurol Scand* 1997; 96(1):14-21.

5. Shakar SK, Gourie-Devi M, Shankar L, et al. Pathology of Madras Type of Motor Neurone Disease (MMND)-a histological and Immunohistochemical Study. *Acta Neuropathol (Berl)* 2000; 99(4):428-34.

6. Wadia R. Atypical forms of Motor Neurone Disease in India. In: Brown R, Meininger V, Swash M, editors. *Amyotrophic Lateral Sclerosis*. 1st ed. London; Martin Dunitz Ltd, 2000: 71-79.

Report of the First Case of Madras Motor Neuron Disease

Forooghi pour M.(MD.), Azar pazhooh M.R.(MD.), Roodbari S.A.(MD.), Amiri H.(MD.),
Bahar Vahdat H.(MD.)

Abstract

Introduction: Motor neuron disorders are a group of Neurodegenerative disorders which consist of degeneration of lower motor neurons and corticospinal tract. Sometimes there is involvement of medallary motor nuclei.

In these group there is no involvement of sensory and autonomic systems. Madras pattern of Motor Neuron Disease (MMND) is mostly seen in southern India. Most of cases is being below 30 years of age. Classic features of disease include bulbar palsy with involvement of seventh to twelfth cranial nerves, sensori-neural deafness, weakness and atrophy of muscles of limbs and rarely optic atrophy and cerebellar signs.

Case study: Our patient was a 16 years old girl who has sensori-neural hearing loss since 10 years before admission with a progressive course until 10 years of age. Weakness of limbs has started about 3 years before admission with a progressive course and bulbar palsy has started since 3 months before admission.

Clinical and paraclinical studies were compatible with diagnosis of MMND.

Results and Conclusion: MMND was reported rarely from other countries except India. Our case has characteristic features of MMND and there was no other report of MMND from Iran yet. Our patient had more progressive course rather than most of other reported cases.

Key words: Amyotrophic Lateral Sclerosis/ Hearing Loss, Sensorineural/ Motor Neuron Disease