



. ( )

ALOKA 288

/ MH

. ( ) ELISA

spss.10

. ( )

(% / )

)

(% / )

(% /

. ( ) (Acoustic shadow)

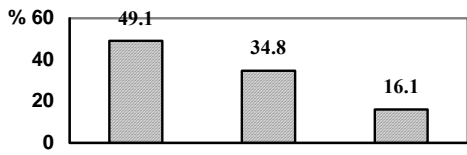
( )	( )	( )	( )
( / )	( / )	( / )	<
( / )	( / )	( / )	
( / )	( / )	( / )	>
( )	( / )	( / )	

. ( )

. ( )

(% )

(% )



(% / )

(% / )

.( )

.( )

.( )

/		
/		
/		
/		

				/		/			
		/				/			
		/		/		/		/	

									( )
		/		/		/		/	<
		/		/		/		/	
		/		/		/		/	>
		/		/		/		/	

---

Bassily

.( )

(% / )

.( )

(% / )

)

(%

%

(% )

(% )

(% )

(CBD Common Bile Duct)

(% / )

CBD

(% / )

(% / )

.( )

Pandolfo

/

Oral

) OCG

( cholecystography

.( )

.( )

MRI

- 
1. Parija S.C., Trematode Infection, Electronic Medicine, last updated April 10, 2003, 1-20.
  2. Boray J C. Experimental Fascioliasis in Australia . *Adv Parasitol* 1969; 7:95-210.
  3. Acosta – Ferreira W, Vercelli-Retta J, Falconi L M. Fasciola Hepatica Human Infection. Histopathological Study of Sixteen Cases; *Virchows Arch A Pathol Anat Histol* 1979; 383(3):319-27.
  4. Totev T, Georgiev E. Fascioliasis, a cause of Mechanical Jaundice. *Khirurgiia (Sofia)* 1979; 32(4): 3578.
  5. Chitchang S, Mitarnum W, Ratananikom N. Fasciola Hepatica M Human pancreas. A Case Report. *J Med Assoc Thai* 1982; 65(6): 345-9.
  6. Garcia- Rodriguez J A, et al. Fascioliasis in Spain: A Review of the Literature and Personal Observations. *Eur J Epidemiol* 1985; 1(2): 121-6.
  7. Espino A M, Millan JC, Finlay C M. Detection of Antibodies and Circulating Excretory-Secretory Antigen for Assessing Cure in Patients with Fascioliasis. *Trans R Soc Trop Med Hyg* 1992; 86(6): 649.
  8. Arjona R, Riancho JA, Aguado JM, Salesa R, Gonzalez- Macias J: Fascioliasis in Developed Countries: A Review of Classic and Aberrant Forms of the Disease *Medicine (Baltimore)* 1995; 74:13-23.
  9. Kabaalioglu A, et al. Fascioliasis: US,CT and MRI Findings with New Observations. *Abdom Jmaging* 2000; 25:400-404.
  10. Jimenez C, Jimenez FJ, Hoyos ML, Monllau A. Hepatic Fascioliasis: the Usefulness of C.T and U.S. *Rev Esp Enferm Dig* 1995; 87:397-398.
  11. Bassily S, et al. Sonography in Diagnosis of Fascioliasis. *Lancet* 1989; 1(8649):1270-1.
  12. Mas-Coma S. Human Fascioliasis. A Review of Pathology Symptomatology, Clinical Manifestation, Diagnosis and Treatment Presented on 2001, June. Guilan Province . Iran. *GLDRC* .
  13. Ruiz Rebollo ML, et al. Echography in the Diagnosis of Fascioliasis. *Rev ESP Enferm Dig* 1991; 79(4): 297-8.
  14. Sherlock S, Dooley J. Disease of the Liver and Biliary System. Oxford, Blackwell Science, 2002: 519.
  15. Richter J, Freise S, Mull R. et al Fascioliasis: Sonographic Abnormalities of the Biliary Tract and Evolution after Treatment with Triclabendasole. *Tropical Medicine and International Health* 1999; 4: 774-781.
  16. Pandolfo I, Zimbaro G. Ultrasonographic and Cholecystographic Finding in a Case of Fascioliasis of the Gallbladder. *J Clin Ultrasound* 1991; 505-507.

---

## The Sonographic Findings in Human Fascioliasis

Alizadeh A.(MD.) Mansour Ghanaii F.(MD.) Sobhani A.R.(Ph. D.)

### Abstract

**Introduction:** Human Fascioliasis is a commonplace infection caused by leaf-shaped Trematode “Fasciola hepatica” incidentally affects a human host. It seems that the incidence of infection is increasing in worldwide. Human Fascioliasis has differentially diagnosed from hepatobiliary diseases such as acute hepatitis, neoplasms and other liver infections.

Diagnosis of the disease is achieved by locating the ova either in feces or duodenal drainage or by serologic studies. Imaging techniques are the most useful methods for confirming the diagnosis and also follow up of treatment. In this article, we present Ultrasonographic features of human Fascioliasis in the hepatitis phase to differentiate it from lesions such as metastasis and primary malignant liver tumor.

**Objective:** Survey the sonographic findings role in Human Fascioliasis.

**Materials and Methods:** 248 patients were selected from 1998 to 1999. All of patients referred by gastroenterologists and infectious disease specialists. Our sonographic apparatus brand was ALOKA 288 with 3.5 MHZ probe in a private clinic. Sonographic study could be helpful to differentiate hepatic fascioliasis from tumoral liver disease. Data were collected and analyzed by SPSS.10 software. We used Chi-Square Test for analysis. P value less than 0.05 was considered significant.

**Results:** 78 (31.5%) were males and 170 (68.5%) were females. A majority of involvement patients aged 20-40 years. 45.2% had paranchymal involvement, 7.3%, 13.7%, 4.8% had Biliary Tracts involvement, Gall bladder infection by worms and involvement of both liver and Biliary Tracts, respectively. There was no abnormal findings in 29% of patients. The most frequent site of liver involvement was posterior segment of right lobe. There was no significant difference between site of involvement and sex or age groups.

**Conclusion:** Ultrasonography can play an important role in the diagnosis of Human Fascioliasis.

**Key words:** Fasciola Hepatica/ Fascioliasis/ Ultrasonography