
*

**

*

*

**

/ / :

/ / :

/ :

/)

()

CT Scan × mm

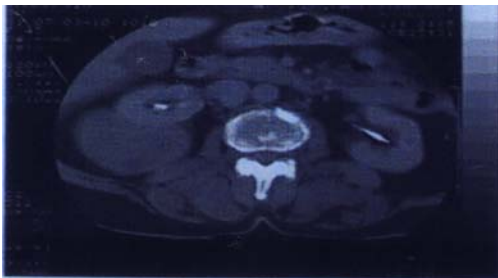
()

(% /

()

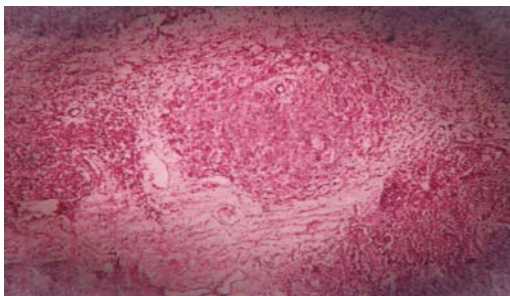
()

.()



(well defined)

/ /



CT .()

(Well-demarcated)

.()

.()

.()

1. Maeshima S, Nakamura H, Nishikawa M, et al. Retroperitoneal Schwannomas Simulating Adrenal Tumors. Clin Imaging 1992; 16:121-2.

2. Rodriguez DD, Edreira R A, Garcia MB, et al. Retroperitoneal Benign Schwannomas, Report of a New Case. Acta Urol Esp 2000; 24(8):685-8.

3. Perhoniemi V, Anttinen I, Kadri F, Saario I. Benign Retroperitoneal Schwannomas Scand J Urol Nephrol 1992; 26:85-7.

4. Kuo CH, Changchien CS. Sonographic Features of Retroperitoneal Neurofibroma. J Clin Ultrasound 1993; 21:309-12.

5. Kim SH, Chio BI. Retroperitoneal Neurofibroma CT and MRI Finding. AJR 1992; 159: 1023-6.

6. Ben Moualli S, Ben Amma M, et al. Retroperitoneal Schwannoma. Case Report Ann Urol (Paris) 2001; 35(5): 2700-2.

Key words: Neurofibroma/ Retroperitoneal/ Neoplasms